

Pyogenic Granuloma: A Clinical Report

Poonacha. K. S, M.D.S*, Shirol Dayanand, M.D.S**, Rashmi Venkatesh***

Abstract

Gingival enlargements in children are a relatively common finding and are usually the result of a reactive response to local irritation or trauma. Pyogenic granuloma is one of the common gingival lesions affecting the children, particularly girls of pubertal age and can grow at a significant rate. A case report of a 12 year old girl who presented with pyogenic granuloma and was successfully treated is presented.

Keywords: Pyogenic granuloma; Gingival growth; Inflammatory hyperplasia; Granuloma pyogenicum.

Introduction

In children gingival lesions are relatively common and can exhibit an exuberant growth in a relatively short period of time. Pyogenic Granuloma (PG) is one such lesion, usually solitary, lobulated benign vascular proliferation of mucous membrane or skin presenting as hemorrhagic, sessile or pedunculated growth.

The PG develops as a result of minor trauma to tissue that allows a non specific infection by microorganisms of low virulence; the tissue response is characterized by an overzealous proliferation of a vascular type of tissue.¹ The term PG is a misnomer since the condition is not associated with pus and does not represent a granuloma histologically.² Most studies demonstrate a definite female predilection, this is attributed to the vascular effect of female hormones that occur in women during puberty, pregnancy and menopause. The

lesions tend to occur more often during the second and third trimester of pregnancy and such lesions are referred to as "pregnancy tumor".³

Case history

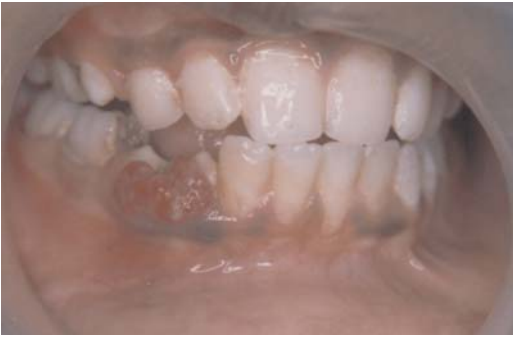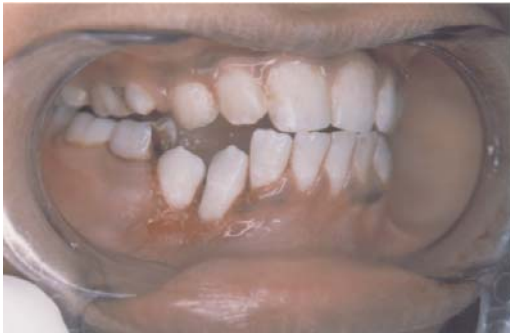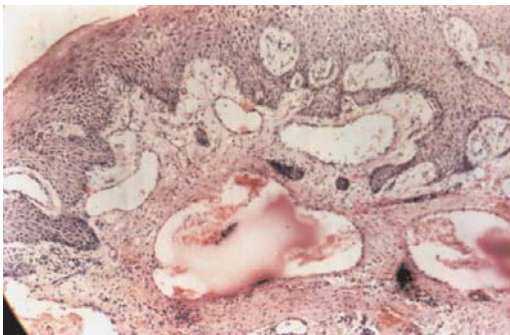
A 12 year old girl reported with the chief complaint of soft tissue growth in the right back tooth region (Figure 1). The tissue started growing on its own since one month to the present dimension. The tissue was painless and bled during tooth brushing and occasionally on its own. On intraoral examination a red coloured soft tissue mass of the dimension 2cmX1cm with surface ulcerations was present on the buccal aspect of erupting 43 and 44. 85 had deep proximal mesio occlusal carious lesion. Intra oral periapical radiograph revealed no abnormality (Figure 2). The lesion was provisionally diagnosed as PG and after routine blood examinations it was decided to conduct excisional biopsy (Figures 3&4). 85 was extracted after the biopsy so as not to get confused with the bleeding area. Periodontal pack was placed after excision for a week to prevent trauma and promote healing. Histopathological slide under 10X magnification in light microscope showed numerous endothelium lined vascular channels, inflammatory cell infiltrate mainly consisting of plasma cells and lymphocytes confirming the lesion as PG (Figure 5). The area showed normal healing in the follow up visit (Figure 6).

Author's Affiliation: *Sr. Lecturer, Dept. of Pedodontics, K.M. Shah Dental College and Hospital, Pipariya, Waghodia road, Vadodara, Gujarat. **Reader, Dept. of Pedodontics, Bharati Vidyapeeth University, Pune, Maharashtra, ***Sr. Lecturer, Dept. of Oral medicine and radiology, K.M. Shah Dental College and Hospital, Pipariya, Waghodia Road, Vadodara, Gujarat.

Reprints Requests: Dr. Poonacha K.S, M.D.S, Sr. Lecturer, K.M. Shah Dental College and Hospital, Pipariya, Waghodia road, Vadodara Dist. Gujarat -391760. India.

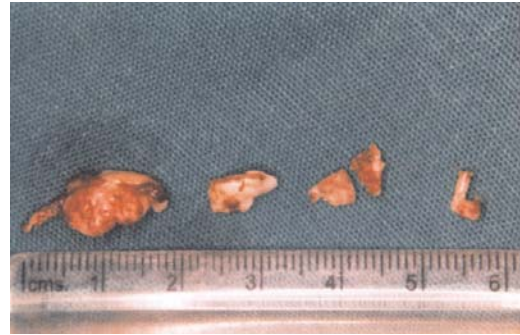
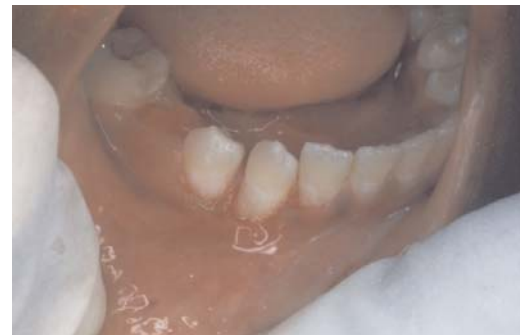E-mail: poochi2263@yahoo.com

(Received on 25.02.2011, accepted on 30.03.2011)

Figure 1 : Soft tissue growth**Figure 3 : Surgical excision****Figure 5 : Slide showing granulation tissue, chronic inflammatory cells, blood vessels & collagen fibers**

Discussion

The term "Pyogenic granuloma" or "Granuloma pyogenicum" was introduced by Hartzell in 1904.⁴ PG possibly originates as a response of tissues to minor trauma and for chronic irritation, this opens a pathway for invasion of non-specific microorganisms, although microorganisms are seldom demonstrated within the lesion.⁵ The lesion is usually slow, asymptomatic and painless. The surface is characteristically ulcerated and

Figure 2 : IOPA showing no abnormality**Figure 4 : Excised tissue****Figure 6 : Healed lesion after one week**

friable which may be covered with a yellow, fibrinous membrane and its colour changes from pink to red to purple depending on the age of the lesion.

Various names suggested for PG are granuloma gravidarum/ pregnancy tumor, Crocker and Hartzell's disease, vascular epulis, benign vascular tumor, hemangiomas granuloma, epulis telangiectatum granulomatose and lobular capillary hemangioma.² Some factors such as inducible nitric oxide synthase, vascular endothelial growth factor, basic fibroblast

growth factor or connective tissue growth factor are known to be involved in angiogenesis and rapid growth of PG.⁴ It occurs most commonly in the maxillary anterior labial gingiva, followed by the lips, tongue, buccal mucosa, palate, mucolabial or mucobuccal fold and alveolar mucosa of edentulous areas.⁶ Clinically it is difficult to differentiate between most of the reactive gingival lesions particularly in the initial stages.⁷ It has also been thought that this lesion represents a benign neoplasm, a form of capillary hemangioma, rather than a reactive infection or traumatic process.⁸

Histologically it has been suggested there are two types of PG, the first type is characterized by proliferating blood vessels that are organized in lobular aggregates although superficially the lesion frequently undergoes no specific change including edema, capillary dilatation or inflammatory granulation tissue reaction. This histological type of PG was called Lobular Capillary Hemangioma (LCH type), whereas the second type (non LCH type) consists of highly vascular proliferation that resembles granulation tissue. Differential diagnosis of PG includes peripheral giant cell granuloma, peripheral ossifying fibroma, metastatic cancer, hemangioma, pregnancy tumor, conventional granulation tissue, hyperplastic gingival inflammation, Kaposi's sarcoma, bacillary angiomatosis, angiosarcoma and non Hodgkin's lymphoma.⁴

If the lesion is small, painless and free of bleeding, clinical observation and follow up are advised. Other treatment methods used are excisional biopsy, Nd: YAG laser, CO₂ laser, flash lamp pulsed dye laser and

cryosurgery, injection of ethanol into the lesion and sodium tetradecyl sulfate sclerotherapy.⁴

Acknowledgements

Dr. Shigli AL, Dr. Shivayogi Hugar, Dr. Ravindranath Reddy, , Dr. Roshan NM, Dr. Santosh S, Dr. Varun Sardana.

References

1. Baumgartner JC, Stanley HR, Salomone JL. Zebra Hunt, part 2: *Journal of Endodontics*, 1991; 17: 182-85.
2. Patil K, Mahima VG, Lahari K. Extralingival pyogenic granuloma. *Indian Journal of Dental Research* 2006; 17: 199-02.
3. Sapp JP, Eversole LR, Wysocki Gp. *Contemporary oral and maxillofacial pathology* (2nd ed.) Mosby, St. Louis; Missouri, 2004; 318-19.
4. Jafarzadeh H, Sanatkhan M, Mohtasham N. Oral pyogenic granuloma: a review. *Journal of Oral Science* 2006; 48 (4): 167-75.
5. Rajendran R, Sivapathasundaram. *Shafer's textbook of oral pathology* (6th ed.) Elsevier; Noida, 2009; 328-30.
6. Angelopoulos AP. Pyogenic granuloma of the oral cavity: statistical analysis of its clinical features. *Journal of Oral Surgery* 1971; 29: 840-47.
7. Poonacha KS, Shigli AL, Shirol D. Peripheral ossifying fibroma: a clinical report. *Contemporary Clinical Dentistry* 2010; 1: 54-56.
8. Willies-Jacobo LJ, Isaacs H, Stein MT. Pyogenic granuloma presenting as a congenital epulis. *Archives of Pediatric Adolescent Medicine* 2000; 154: 603-05.